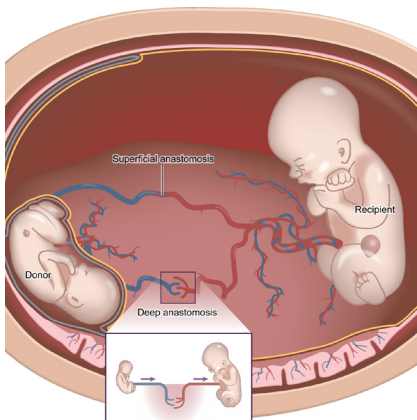


Fetal Distress Condition



Twin-to-Twin Transfusion Syndrome (TTTS)

Twice as many babies die from TTTS and other fetal syndromes than from SIDS (Sudden Infant Death Syndrome) each year; yet more people are aware of SIDS.



Description

TTTS or Twin-to-Twin Transfusion Syndrome is a disease of the placenta. It affects pregnancies with monochorionic (shared placenta) multiples when blood passes disproportionately from one baby to the other through connecting blood vessels within their shared placenta. One baby, the recipient twin, gets too much blood overloading his or her cardiovascular system, and may die from heart failure. The other baby, the donor twin or stuck twin, does not get enough blood and may die from severe anemia. Left untreated, mortality rates near 100%.

The cause of TTTS is attributed to unbalanced flow of blood through vascular channels that connect the circulatory systems of each twin via the common placenta. The shunting of blood through the vascular communications leads to a net flow of blood from one twin (the donor) to the other twin (the recipient). The donor twin develops oligohydramnios (low amniotic fluid) and poor fetal growth, while the recipient twin develops polyhydramnios (excess amniotic fluid), heart failure, and hydrops. If left untreated, the pregnancy may be lost due to lack of blood getting to the smaller twin, fluid overload and heart failure in the larger twin, and/or preterm (early) labor leading to miscarriage of the entire pregnancy.

Some general treatment approaches consist of using laser energy to seal off the blood vessels that shunt blood between the fetuses. Because the surgical approach is via an operative fetoscope, there is minimal risk to the mother. Laser therapy for TTTS has been shown to provide improved pregnancy outcomes compared to alternative therapies. Although all treatment options should be discussed with your fetal surgeon.

Frequency

1 in 7 monochorionic pregnancies are afflicted with TTTS.

Diagnosis & Staging

The in utero diagnosis of TTTS is established by ultrasound. First, the presence of a shared placenta (monochorionic) confirmed. Ultrasounds performed earlier in the pregnancy may be useful in establishing the chorionicity (number of placentas). Ultrasound findings such as a single placenta, same fetal sex, and a "T-sign" in which the dividing membrane inserts perpendicular to the placenta are helpful in diagnosing a monochorionic twin gestation.

Fetal Distress Condition



TTTS is then diagnosed simply by assessing the discordance of amniotic fluid volume on either side of the dividing fetal membranes. The maximum vertical pocket (MVP) of amniotic fluid volume must be greater than or equal to 8.0 centimeters in the recipient's sac, and less than or equal to 2.0 centimeters in the donor's sac.

Although TTTS is diagnosed via ultrasound, women with a monochorionic or monoamniotic pregnancy can be alerted to certain symptoms that may require medical attention. Symptoms may include a sudden increase in the size of the pregnant belly, a sudden increase in fatigue or pressure in the belly or back, and/or sudden unexplained increase in weight (eg. 7 lbs in a week or less).

Once the diagnosis of TTTS is established, the severity of the condition may be assessed using the Quintero Staging System, as listed below. This staging system is based on the observations of several hundred patients with TTTS. Not only does this staging system mirror the progression of disease, but it has also been shown to be important in establishing the prognosis. An atypical presentation of TTTS may occur if the fetal bladder of the donor twin remains visible despite the presence of critically abnormal fetal Dopplers or hydrops.

Quintero Staging System

Stage I: The fetal bladder of the donor twin remains visible sonographically.

Stage II: The bladder of the donor twin is collapsed and not visible by ultrasound.

Stage III: Critically abnormal fetal Doppler studies noted. This may include absent or reversed end-diastolic velocity (flow) in the umbilical artery, absent or reverse flow in the ductus venosus (liver), or pulsatile flow in the umbilical vein.

Stage IV: Fetal hydrops present.

Stage V: Demise of either twin.

Management Options & Outcomes

Untreated, TTTS that presents before 28 weeks gestation is associated with approximately a 90% mortality rate. Because of the dismal prognosis of TTTS, various treatment methods have been advocated. Recent studies have shown improved outcomes in patients treated with laser therapy compared to the traditional method of serial amnioreductions (Quintero, AJOG, 2003; Senat, NEJM, 2004). In the European randomized trial, the study was interrupted prematurely because statistical improvement in pregnancy outcome in the laser therapy group was achieved at the time of an interval analysis (Senat, NEJM, 2004).

Treatment Options

- Laser Surgery:** This surgical approach utilizes an operative fetoscope to deliver laser energy that then seals off the offending blood vessels on the surface of the common placenta. Because the vascular connections between the two fetuses are sealed, no further blood exchange between the fetuses takes place, thus eliminating the syndrome. Pregnancy outcomes after laser therapy for TTTS is as follows: approximately 85% of patients will have at least one fetus survive, 50% will have both survive, with a 5% risk of neurologic sequelae such as cerebral palsy. These results remain consistent regardless of Quintero Stage (i.e. severity).
- Expectant Management:** In this option the pregnancy would be followed with serial ultrasound examinations. There is approximately a 90% pregnancy loss rate in cases of TTTS diagnosed before 28 weeks gestation.



Fetal Distress Condition

3. **Amnioreduction:** The purpose of this procedure is to remove excess amniotic fluid from the recipient's sac in order to prevent premature birth or miscarriage. This procedure is done via a needle placed using ultrasound guidance. Because this approach does not treat the underlying cause of TTTS, amniotic fluid excess may recur, resulting in the need for multiple amnioreductions. Overall, the success rate of this treatment approach is approximately 66% chance of at least one fetal survivor, with an incidence of 15% chance of brain damage. Unlike laser therapy, the risk of fetal death and neurologic sequelae increases with increasing Quintero Stage.
4. **Fetal Septostomy** has been suggested as a treatment option for TTTS. This procedure entails the purposeful needling of the dividing membrane in the hopes to equalize the amniotic fluid within each sac. Studies have not shown improved outcomes using this approach. Moreover, the disruption of the dividing membrane may result in cord entanglement, which may be an additional cause of fetal death. Generally this procedure is not advised.
5. **Umbilical Cord Occlusion:** This procedure utilizes an operative fetoscope to interrupt the flow of blood through the umbilical cord of one of the fetuses. This fetus dies and remains inside the uterus for the duration of the pregnancy. The remaining twin will have an 85% chance of survival, and 5% risk of brain damage. Because the risks of this procedure are similar to laser therapy, but laser therapy provides the additional benefit of the chance of survival for both twins, this procedure is generally not offered for the treatment of TTTS unless the demise of one twin is a foregone conclusion due to fetal anomalies and condition.

Candidacy for Laser Surgery

To generally qualify for laser surgery, the following criteria usually must be met:

Inclusion Criteria

1. Gestational age: 16 weeks 0 days to 26 weeks 0 days.
2. Diagnosis of TTTS:
 - Single (shared placenta) with thin dividing membrane (or no dividing membrane in the case of monoamniotic twins).
 - Polyhydramnios: maximum vertical pocket of 8 centimeters or more in the recipient twin, prior to amnioreduction.
 - Oligohydramnios: maximum vertical pocket of 2 centimeters or less in the donor twin, prior to amnioreduction.
 - Same gender, if visible.

General Exclusion Criteria

1. One or both babies have other major birth defects.
2. Genetic studies showing an uncompensated abnormality.
3. A hole in the dividing membrane that was intentionally made.
4. Ruptured fetal membranes (leakage of amniotic fluid from the vagina).
5. Chorioamnionitis (infection in the uterus).
6. Ultrasound evidence of brain damage of either fetus.
7. Placental abruption (separation of the placenta from the uterus).
8. Active labor.

Fetal Distress Condition



Laser Surgery - Details of Procedure

Most surgeries are performed under local anesthesia with some intravenous sedation. A small incision (3 millimeters or about 1/10th of an inch) will be made and a trocar (small metal tube) will be inserted into the amniotic sac of the recipient twin. Amniotic fluid may be sent for genetic and microbiology studies. An endoscope (medical telescope) will be passed into the uterus. The blood vessels, which are visible on the surface of the placenta, will be analyzed, and all communicating vessels will be sealed off with laser energy. A second trocar may have to be inserted to complete the surgery, particularly if the placenta is anterior. At the conclusion of the surgery, the excess amniotic fluid may be drained from the sac of the recipient twin. You will be given antibiotics before and after surgery.

Laser Surgery - Postoperative Care

Typically, you will remain in the hospital for 1 to 2 days after surgery. You will then be sent home to the care of your primary obstetrician and perinatologist. Weekly ultrasound is recommended for the four weeks after surgery. Then, depending on the clinical circumstances, follow up ultrasounds generally should be performed every 2 - 3 weeks for the duration of the pregnancy (however it is the recommendation of Fetal Hope to have weekly monitoring via ultrasound, NST's, or other appropriate means.).

Additional Information (Nutrition)

If TTTS is diagnosed in its early stages some physicians will recommend a wait and see approach. Under this approach the mother is usually encouraged to consume increased amounts of protein, often through protein drinks like Boost or Ensure. Some physicians incorrectly indicate that TTTS can be "cured" by bed rest and proper nutrition (usually an increase in protein through protein drinks). Most studies indicate, regardless of a TTTS diagnosis, most pregnant women with multiples suffer malnutrition due to the nutritional needs of more than one fetus on the woman. Fetal Hope does promote proper nutrition including increase in nutritious foods such as fruit, vegetables and an increase in protein via lean meats and/or protein supplements. Providing proper nutrition to the pregnant mother will only allow her to be stronger for the pregnancy and for her babies to have more than adequate nutrition for their growth.

Additional Resources

For additional resources, including articles and medical information, please visit www.fetalhope.org.